

DATE PRESENTING CLINICAL SIGNS

12/20/21

History: Grade 3/4 murmur.

ECHOCARDIOGRAPHIC FINDINGS

PERFORMED BY:

2D, M-mode, and Doppler study.

Potomac Mobile
Veterinary
Ultrasound

There is mild left atrial dilation. The mitral valve appears normal, though mild mitral regurgitation is present. There is mild left ventricular dilation. There is mild hypertrophy of the interventricular septum, as well as the left ventricular papillary muscles. Left ventricular posterior wall thickness is normal. Left ventricular systolic function is normal. The aorta and aortic appear normal, though there is mildly increased flow velocity in the ascending aorta. Right atrial and right ventricular dimensions are normal. The tricuspid valve appears normal, though trivial tricuspid regurgitation is present. The pulmonary artery and pulmonic valve are normal. No heartworms are visualized. No pericardial effusion or cardiac masses are seen.

INTERPRETED BY

Keith Blass, DVM,
MS, DACVIM
(Cardiology)

PATIENT

Linxie FOHA

LA - 17.3 mm
LA/Ao - 1.60
IVSd - 6.0 mm
LVPWd - 5.5 mm
LVIDd - 15.6 mm
LVIDs - 5.1 mm
FS - 67%
LVOT - 1.25 m/s
RVOT - 0.81 m/s

SPECIES

Feline

ASSESSMENT/RECOMMENDATIONS

BREED

Hypertrophic cardiomyopathy (HCM)

DSH

This examination demonstrates hypertrophy of Linxie's interventricular septum and left ventricular papillary muscles, consistent with the presence of HCM. Secondary to his hypertrophy, Linxie has mild dilation of his left atrium. The presence of only mild left atrial dilation indicates that Linkie's current risk for the development of congestive heart failure and/or thromboembolic disease is not significantly elevated, however, careful monitoring for clinical signs associated with these conditions is recommended.

SEX

MN

I recommend starting Linxie on clopidogrel (18.75 mg SID), as this medication should help to reduce his risk for cardiac thrombus formation.

AGE

6 y

A recheck echocardiogram is recommended in 6 months. Thoracic radiographs are recommended if Linxie experiences respiratory clinical signs.

WEIGHT

11 lb

HOSPITAL NAME

Companion Paws
Mobile Vet

REFERRING VET

Dr. Jarrett



DATE

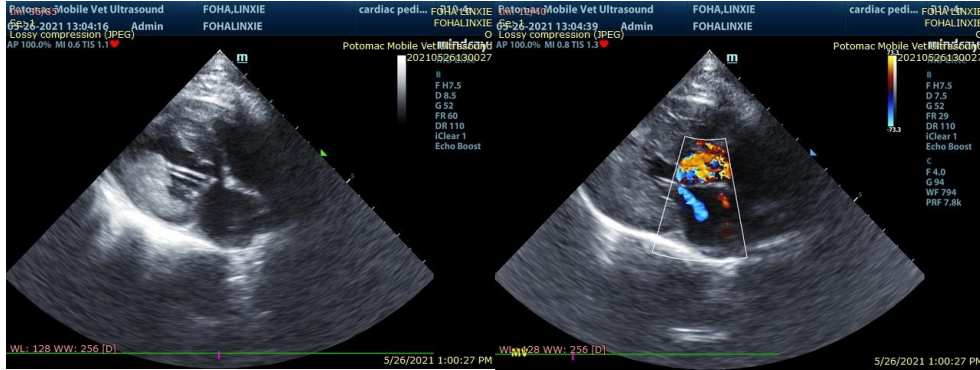
12/20/21

PERFORMED BY:

Potomac Mobile
Veterinary
Ultrasound

INTERPRETED BY

Keith Blass, DVM,
MS, DACVIM
(Cardiology)



The information and recommendations provided are based on the images presented by the referring veterinarian. No evaluation can be communicated regarding pathology that was not visible in the image/video clips provided.

Thank you for this referral. If the clinical or image interpretation does not parallel your findings or if I can be of any further assistance please contact me.

PATIENT

Linxie FOHA

Keith Blass, DVM, MS, DACVIM (Cardiology)
KeithBlass@gmail.com
631-804-5754

SPECIES

Feline

BREED

DSH

SEX

MN

AGE

6 y

WEIGHT

11 lb

HOSPITAL NAME

Companion Paws
Mobile Vet

REFERRING VET

Dr. Jarrett